

## RESEARCH ARTICLE

# A Low Concentration of Tacrolimus/Semifluorinated Alkane (SFA) Eyedrop Suppresses Intraocular Inflammation in Experimental Models of Uveitis

S. De Majumdar<sup>1</sup>, M. Subinya<sup>2</sup>, J. Korward<sup>3</sup>, A. Pettigrew<sup>2</sup>, D. Scherer<sup>2</sup> and H. Xu<sup>\*1</sup>

<sup>1</sup>The Wellcome-Wolfson Institute of Experimental Medicine, School of Medicine, Dentistry and Biomedical Sciences, Queen's University Belfast, Belfast, UK; <sup>2</sup>Formulation Development, Novaliq GmbH, Im Neuenheimer Feld 515, DE-69120 Heidelberg, Germany; <sup>3</sup>Preclinical Development, Novaliq GmbH, Im Neuenheimer Feld 515, DE-69120 Heidelberg, Germany

**Abstract: Purpose:** Corticosteroids remain the mainstay therapy for uveitis, a major cause of blindness in the working age population. However, a substantial number of patients cannot benefit from the therapy due to steroids resistance or intolerance. Tacrolimus has been used to treat refractory uveitis through systemic administration. The aim of this study was to evaluate the therapeutic potential of 0.03% tacrolimus eyedrop in mouse models of uveitis.

**Methods:** 0.03% tacrolimus in perfluorobutylpentane (F4H5) (0.03% Tacrolimus/SFA) was formulated using a previously published protocol. Tacrolimus suspended in PBS (0.03% Tacrolimus/PBS) was used as a control. In addition, 0.1% dexamethasone (0.1% DXM) was used as a standard therapy control. Endotoxin-induced uveitis (EIU) and experimental autoimmune uveoretinitis (EAU) were induced in adult C57BL/6 mice using protocols described previously. Mice were treated with eyedrops three times/day immediately after EIU induction for 48 h or from day 14 to day 25 post-immunization (for EAU). Clinical and histological examinations were conducted at the end of the experiment. Pharmacokinetics study was conducted in mice with and without EIU. At different times after eyedrop treatment, ocular tissues were collected for tacrolimus measurement.

**Results:** The 0.03% Tacrolimus/SFA eyedrop treatment reduced the clinical scores and histological scores of intraocular inflammation in both EIU and EAU to the levels similar to 0.1% DXM eyedrop treatment. The 0.03% Tacrolimus/PBS did not show any suppressive effect in EIU and EAU. Pharmacokinetic studies showed that 15 min after topical administration of 0.03% Tacrolimus/SFA, low levels of tacrolimus were detected in the retina (48 ng/g tissue) and vitreous (2.5 ng/ml) in normal mouse eyes, and the levels were significantly higher in EIU eyes (102 ng/g tissue in the retina and 24 ng/ml in the vitreous). Tacrolimus remained detectable in intraocular tissues of EIU eyes 6 h after topical administration (68 ng/g retinal tissue, 10 ng/ml vitreous). Only background levels of tacrolimus were detected in the retina (2-8 ng/g tissue) after 0.03% Tacrolimus/PBS eyedrop administration.

**Conclusion:** 0.03% Tacrolimus/SFA eyedrop can penetrate ocular barrier and reach intraocular tissue at therapeutic levels in mouse eyes, particularly under inflammatory conditions. 0.03% Tacrolimus/SFA eyedrop may have therapeutic potentials for inflammatory eye diseases including uveitis.

**Keywords:** Tacrolimus, semifluorinated alkane, uveitis, eyedrop, pharmacolinctic.

## 1. INTRODUCTION

Uveitis is an inflammatory condition of the uveal tract of the eye. Clinically, it can be classified into

anterior, intermediate, posterior and pan uveitis based on the part of the uveal tract affected. Anterior uveitis accounts for 60-80% of all uveitis cases [1, 2]. Uveitis remains a significant cause of blindness in people of working age accounting for 10-15% of total blindness in the USA [3]. Uveitis can have infectious or non-infectious (autoimmune) aetiologies. A recent study has shown that the prevalence of non-infections uveitis in

\*Address correspondence to this author at The Wellcome-Wolfson Institute of Experimental Medicine, Queen's University Belfast, 97 Lisburn Road, BT9 7BL, Belfast, UK; Tel: +44 (0)289097 6463; E-mail: [heping.xu@qub.ac.uk](mailto:heping.xu@qub.ac.uk)

the USA is 121 people per 100,000 for adults and 29 per 100,000 for children [4]. However, in Southern India, it has been reported that nearly one in 200 persons may be affected by this condition [5].

Autoimmune uveitis is mediated by retinal antigen specific T lymphocytes, including Th1 and Th17 cells [6, 7], and corticosteroids remain the mainstay therapy for this condition. Anterior uveitis is treated with topical steroids, although systemic immune suppression may be required if patients also have other systemic autoimmune conditions. For posterior uveitis, apart from systemic immune suppression, intravitreal injection of steroids (e.g., dexamethasone, triamcinolone and fluocinolone) is now commonly used. Various intraocular implants have also been developed to improve intraocular drug delivery. Although intravitreal injection of steroids can better control inflammation [8] and cause limited systemic side-effects, local adverse effects remain a major concern. For example, 30-50% of patients developed glaucoma following intravitreal injection of triamcinolone [9]; almost all patients received intravitreal injections of fluocinolone *via* the Retisert implant had glaucoma and 40% of them required surgery to control the pressure [8]. Cataract is another common side-effect, particularly in patients receiving multiple intravitreal steroid injections [10]. Clearly, more effective and safer therapies are urgently needed for uveitis.

Tacrolimus (FK506), a macrolide lactone isolated from fungus, *Streptomyces tsukubaensis* is a potent immunosuppressive drug [11]. Tacrolimus has the same mechanical action of inhibiting T-lymphocyte signal transduction and cell proliferation as cyclosporine, but is 100 times more powerful [12-14]. Tacrolimus is used off label as a second line of therapy for uveitis through systemic administration and is proved to be effective, particularly in steroid-resistance or intolerance patients [15-17]. However, long-term usage can cause tacrolimus intolerance due to severe adverse effects (e.g., nephrotoxicity, hypertension, hyperesthesia, muscular weakness, insomnia, and central nervous system alterations, etc. [18]). Topical formulations of tacrolimus are not available due to the poor solubility and stability of the molecule in aqueous environments.

Semifluorinated alkanes (SFAs) are physically, chemically and physiologically inert, undergo neither catabolism nor metabolism in the human body and have favourable physical properties for use in the eye, including low surface and interface tension leading to excellent spreading properties [19]. Moreover, lipophilic drugs such as tacrolimus can be formulated without the use of surfactants and stabilizers. These properties make them ideal for ocular drug delivery [20]. Among the various SFAs, we explored perfluorobutylpentane (F4H5) for ophthalmic applications. Here we report the therapeutic potential of a novel formula of tacrolimus eyedrop i.e., 0.03% tacrolimus dissolved in F4H5, in mouse models of uveitis, including the endotoxin-induced uveitis (EIU), a model of human anterior

uveitis, and retinal antigen peptide induced experimental autoimmune uveoretinitis (EAU), a model of human posterior uveitis.

## 2. MATERIAL AND METHODS

### 2.1. Animals

Ten- to 12-week-old C57BL/6J mice were supplied by the Biological Resource Unit at the Queen's University Belfast. All procedures adopted conformed to the Home Office Regulations for Animal (Scientific Procedures) Act 1986 (UK) and to the Association for Research in Vision and Ophthalmology Statement for the use of Animals in Ophthalmic and Vision Research. All protocols were approved by the Ethics Committee of the Queen's University Belfast.

### 2.2. Induction of Experimental Autoimmune Uveoretinitis (EAU)

EAU was induced as previously described [21-23]. Briefly C57BL/6J mice were immunized subcutaneously with 500 µg of IRPB peptide 1–20 (GPTHLFQPSLVLDMAKVLLD; GL Biochem, Shanghai Ltd., China) emulsified in complete Freund's adjuvant (CFA, H37Ra, Difco Laboratories, Detroit, MI, USA). Mice were administered with an additional intraperitoneal injection of 100 µl (1.5 µg) of *Bordetella pertussis* toxin (Tocris Bioscience, UK). Retinal inflammation develops at day 12-14 post-immunisation (p.i.), and peaks at day 22-25 p.i. The severity of inflammation declines after the peak stage, however, retinal inflammation remains active for over 4 months [22].

### 2.3. Induction of Endotoxin Induced Uveitis (EIU)

EIU was induced in C57BL/6J mice by intravitreal injection of lipopolysaccharide (LPS) using a previously described protocol [24, 25] with slight modification. In brief, *Escherichia coli* 055:B5 LPS (Sigma, UK) was dissolved in pyrogen-free phosphate buffered saline (PBS). Mice were injected intravitreally with 200 ng/eye LPS in 1 µL using a 30-gage needle and a 25 µL syringe in the Repeating Dispenser (PB600-1, Hamilton, Nevada, USA). Intraocular inflammation begins 4 to 6 hours after the LPS challenge, peaks at 24-48 h, the inflammation then starts to resolve after 3 days [25].

### 2.4. Formulations

A solution of 0.03% w/v of tacrolimus (Zhejiang Hisun Chemical Co., Ltd., China) in 1.4% w/w ethanol (Sigma-Aldrich, Germany) in perfluorobutylpentane (F4H5) (Novaliq GmbH) was formulated according to the procedure detailed in relevant Patents. Tacrolimus suspended in PBS (0.03%) was used as a control. In addition, 0.1% dexamethasone (DXM) (Sigma-Aldrich, UK) was used as a standard therapy control.

## 2.5. Treatment

### 2.5.1. Treatment of EAU

On day 14, EAU mice were divided into four groups based on the clinical score of inflammation and the score in each group was comparable. Group 1: Control (no treatment,  $n = 7$  mice); Group 2: 0.1% Dexamethasone eyedrop (DXM,  $n = 7$  mice); Group 3: 0.03% Tacrolimus/PBS eyedrop ( $n = 7$  mice); Group 4: 0.03% Tacrolimus/SFA eyedrop ( $n = 7$  mice). All mice in groups 2-4 received eyedrop treatment three times a day from day 14 p.i. - day 25 p.i.

### 2.5.2. Treatment of EIU

Mice were randomized into four groups in the EIU study: Group 1: Control (no eyedrops,  $n = 6$  mice); Group 2: 0.1% Dexamethasone treatment,  $N = 6$  mice; Group 3: 0.03% Tacrolimus/PBS,  $n = 6$  mice; Group 4: 0.03% Tacrolimus/SFA,  $n = 8$  mice. All mice were treated with eyedrops three times per day starting immediately after the intravitreal injection of LPS for two days. The study was repeated twice.

## 2.6. Clinical Evaluation of Ocular Inflammation

Animals were anesthetized by isoflurane inhalation (Vet Tech Solutions Ltd., UK) and pupils dilated using 1% atropine and 2.5% phenylephrine (Minims, Bausch and Lomb, UK). The severity of ocular inflammation was evaluated under the microscope taking into consideration of both anterior and posterior inflammation (by fundus examination using the fundus imaging system). The clinical score for anterior uveitis was graded according to a previously defined scoring system (grades 0-4) [26]: **grade 0**, no inflammatory reaction; **grade 1**, discrete inflammation of the iris and conjunctival vessels; **grade 2**, dilation of the iris and conjunctival vessels with moderate flare in the anterior chamber; **grade 3**, hyperemia in the iris associated with the Tyndall effect in the anterior chamber; and **grade 4**, same clinical signs as for 3 plus the presence of fibrin or synechiae. To evaluate retinal inflammation, fundus images were taken from each mouse using the Topical Endoscopic Fundus Imaging (TEFI) system as described previously [26]. Digital images from each eye were analysed and clinical score was assessed by two independent researchers using a standard grading system developed by us previously [26].

## 2.7. Histology

Eyes were collected from day 25 p.i. EAU or day 2 p.i. EIU mice for histological examination. All eyes were fixed in 2.5% (w/v) glutaraldehyde (Agar Scientific Ltd., Stansted, UK) for at least 24 h. Eyes were then embedded in paraffin and processed for haematoxylin and eosin (H&E) staining, and examined using a light microscope (Nikon Eclipse E400 light microscope; Nikon UK Ltd.) For each eye, four sections from four different layers 100  $\mu\text{m}$  apart were graded according to the criteria described previously [27].

## 2.8. Pharmacokinetics study of Tacrolimus/SFA eyedrop

### 2.8.1. Eyedrop Treatment and Groups

The pharmacokinetics of Tacrolimus/SFA eyedrop were conducted in both normal mice and EIU mice. Normal C57BL/6J mice or EIU mice (immediately after LPS injection) were treated with either 0.03% Tacrolimus/SFA or 0.03% Tacrolimus/PBS eyedrops (60  $\mu\text{L}$ /drop) three times per day for three days. At different times (15 min, 30 min, 1 h, 2 h, 4 h and 6 h) after the last eyedrop treatment, animals were sacrificed and the following samples were collected for the measurement of tacrolimus (1) vitreous humour, (2) retina, (3) choroid/sclera, and (4) blood. Four mice were used in each group, and 20 normal mice and 8 EIU mice that did not receive any eyedrop treatment were used as controls.

### 2.8.2. Sample Collection and Processing

(1) Vitreous humour – 6 ~ 8  $\mu\text{L}$  vitreous humour were collected from each mouse. (2) Retina – Retinal tissues were dissected and weighted immediately after sacrificing the animal and put into an Eppendorf tube. (3) Choroid/sclera – Choroid/scleral tissues were dissected and weighted immediately after sacrificing the animal and put into an Eppendorf tube. (4) Blood – 200 ~ 500  $\mu\text{L}$  of whole blood were collected into EDTA-coated tubes from each mouse.

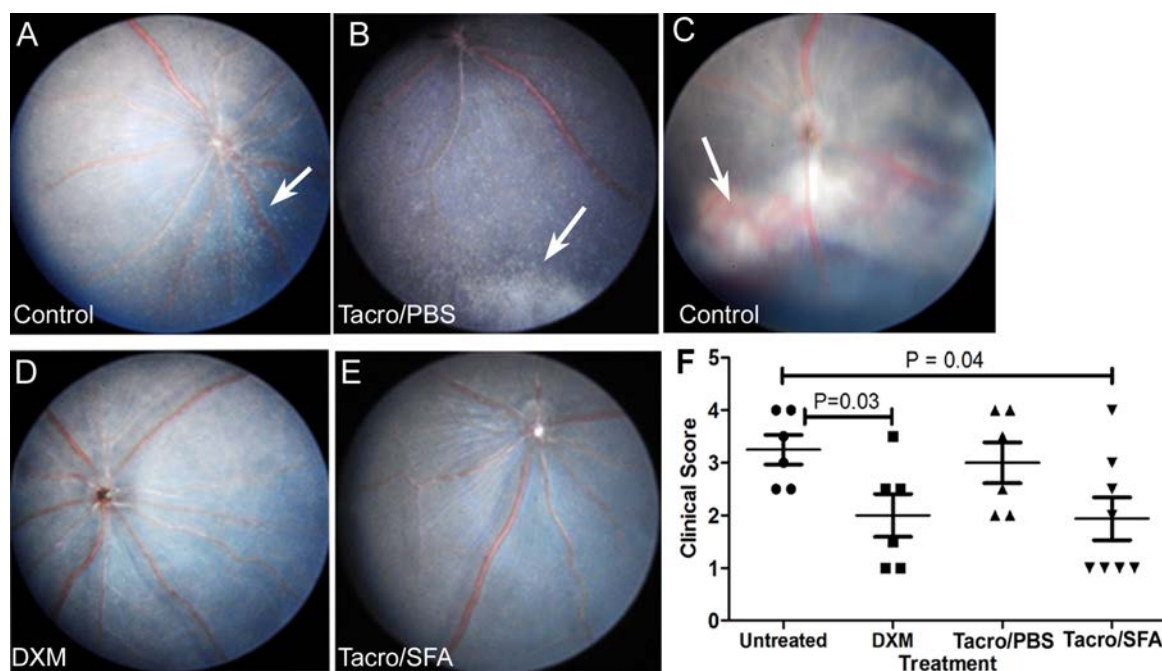
All samples were stored at  $-20^{\circ}\text{C}$  and then shipped to Nuvisan GmbH. Determination of tacrolimus was conducted at Nuvisan GmbH using an internally standardized liquid chromatography tandem mass spectrometry (LC-MS/MS) method, which was qualified for the respective matrices before sample analysis. The lower limit of quantification was 0.25 ng/mL for blood, 0.05 ng/mL for retina and choroid/sclera homogenate, and 1.25 ng/ml for the vitreous.

## 3. RESULTS

### 3.1. The Effect of Tacrolimus/SFA Eyedrop in EIU

Clinical investigation revealed engorgement of conjunctival vessels, massive immune cell infiltration in the anterior chamber and the vitreous of untreated and tacrolimus-PBS treated EIU mice at 48 h (arrows, Fig. 1A, B). Infiltrating cells were more frequently observed in the inferior part of the vitreous body (Fig. 1B). Retinal detachment and haemorrhage were observed in eyes with severe inflammation (arrow, Fig. 1C). The severity of intraocular inflammation was reduced following Dexamethasone (Fig. 1D) or Tacrolimus/SFA (Fig. 1E) treatment compared to control and Tacrolimus/PBS treated groups (Fig. 1F).

Consistent with the clinical signs, histological analysis revealed marked features of EIU characterized by accumulation of immune cells in the anterior chamber (AC), vitreous cavity (Vi), and ciliary body (CB) area in mice with no treatment (Fig. 2A) or



**Fig. (1).** The effects of Tacrolimus/SFA eyedrop on clinical presentations of EIU. EIU was induced in mice by intravitreal injection of 200 ng/ $\mu$ l/eye LPS. Immediately after LPS injection, mice were treated with either 0.1% dexamethasone (DXM), or 0.03% Tacrolimus/PBS, or 0.03% Tacrolimus/SFA eyedrop, 3 times/day. Clinical evaluation including fundus images were conducted after 48 h. (A-E) fundus images from untreated (A, C), Tacrolimus/PBS treated (C), DXM treated (D) and Tacrolimus/SFA treated (E) mice. Arrows in (A) and (B) indicating vitreous infiltrating cells; arrow in (C) indicating retinal haemorrhage. (E) Clinical score of retinal inflammation in different groups. Mann-Whitney test.

Tacrolimus/PBS eyedrop treatment (Fig. 2B). Severe retinal destruction (retinal detachment, disorganised retinal layers, haemorrhage) associated with massive retinal immune cell infiltration was also observed (arrows in Fig. 2A, B). Mild cell infiltration in the vitreous and retina was observed in eyes treated with DXM or Tacrolimus/SFA eyedrops, and the overall architecture of retinal layers remained intact (Fig. 2C, D). The histopathological scores in DXM and Tacrolimus/SFA treated eyes were significantly lower than that from untreated control EIU eyes (Fig. 2E). Repeated studies in additional two sets of mice revealed similar results.

### 3.2. The effect of Tacrolimus/SFA eyedrop in EAU

Having shown that Tacrolimus/SFA eyedrop suppressed inflammation in EIU, we further tested its therapeutic effects in EAU, a mouse model of posterior uveitis. Topical administration of eyedrops was started after the onset of uveitis i.e., 14 days post-immunisation (p.i.). Clinical scores of EAU were comparable between study groups prior to treatment (i.e., day 14). Severe retinal inflammation, characterised by extensive retinal infiltration (whitish lesions, Fig. 3A, B), vascular cuffing (arrows, Fig. 3A), and linear lesions (arrowhead, Fig. 3A) was observed in untreated and Tacrolimus/PBS treated EAU mice. Mild inflammation characterized by discrete small infiltrates, mild vascular cuffing and optic head swelling (Fig. 3C, D) was observed in dexamethasone and Tacrolimus/SFA treated eyes. The severity of retinal

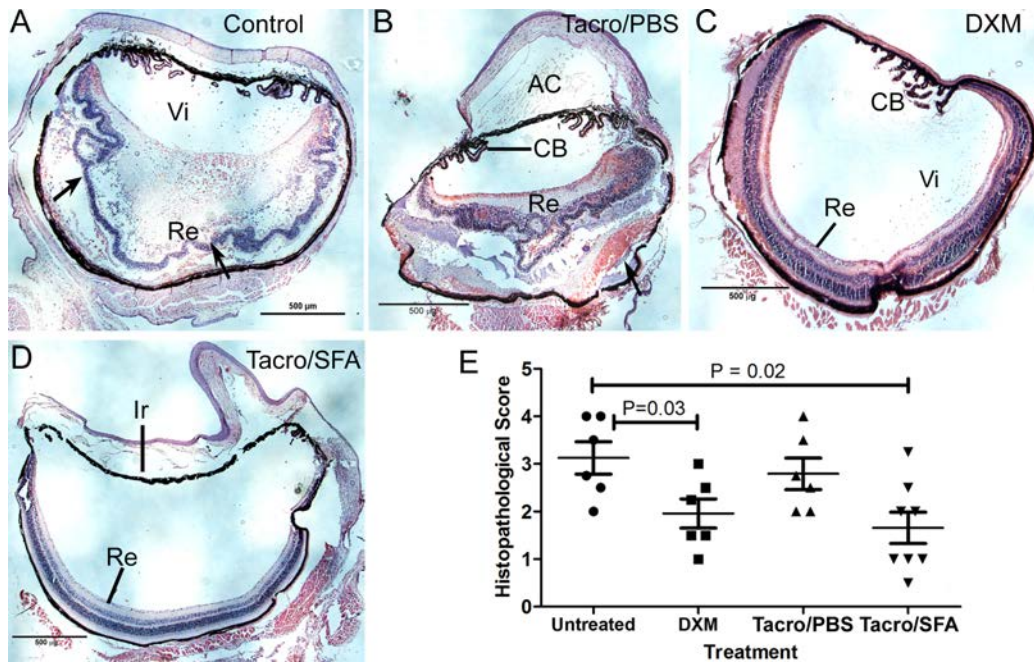
inflammation increased from day 14 to day 25 p.i. in all groups, although the increment was more significant in untreated and Tacrolimus/PBS treated groups compared to Tacrolimus/SFA and DXM treated groups (Fig. 3E). On day 25 p.i., the clinical scores of the DXM and Tacrolimus/SFA treated groups were significantly lower than those from untreated mice (Fig. 3F).

Histological examination revealed massive immune cell infiltration in the retina and vitreous in eyes from untreated (Fig. 4A) and Tacrolimus/PBS treated (Fig. 4C) mice. Retinal layers were disorganised in these eyes. Small numbers of immune cell infiltration and granulomatous lesions (arrows, Fig. 4) were observed in DXM (Fig. 4B) and Tacrolimus/SFA (Fig. 4D) treated eyes, although the retinal structure was largely intact in these mice. The overall histopathological score of EAU was significantly lower in DXM treated and Tacrolimus/SFA treated mice compared to untreated controls (Fig. 4E). Our results suggest that DXM and Tacrolimus/SFA eyedrop is effective for the control of ongoing ocular inflammation in EAU.

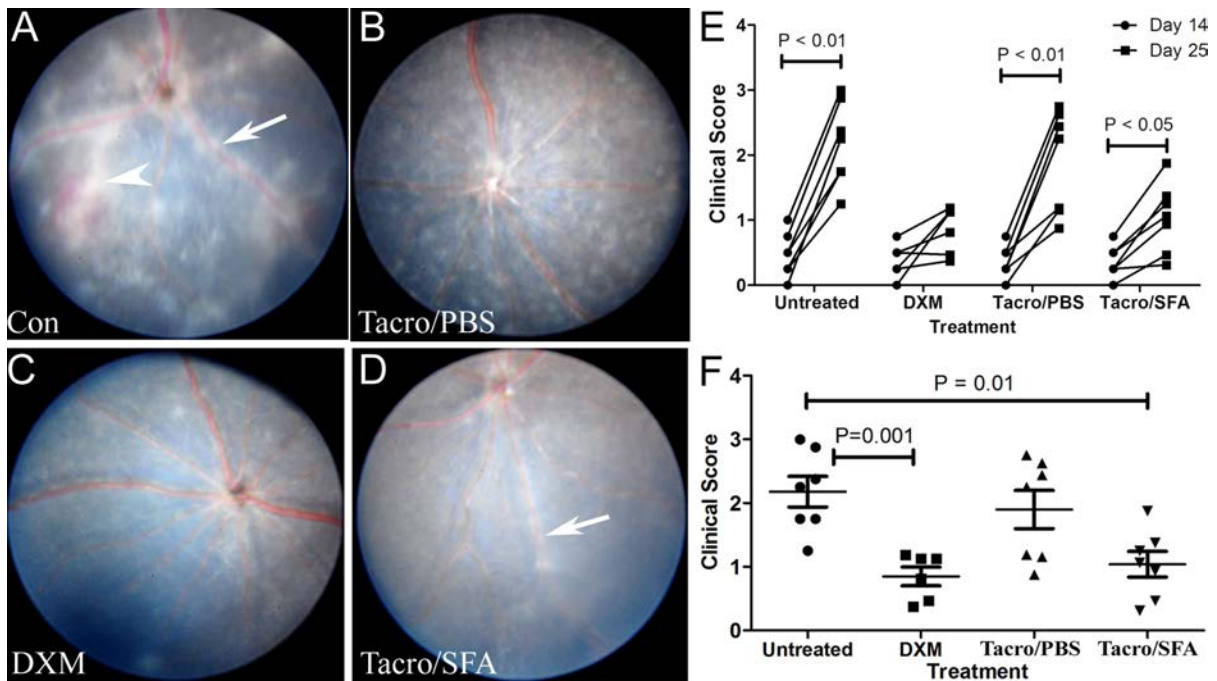
### 3.3. Pharmacokinetics and absorption of tacrolimus eyedrop

#### 3.3.1. Pharmacokinetics and absorption of Tacrolimus eyedrop in normal non-inflamed mice:

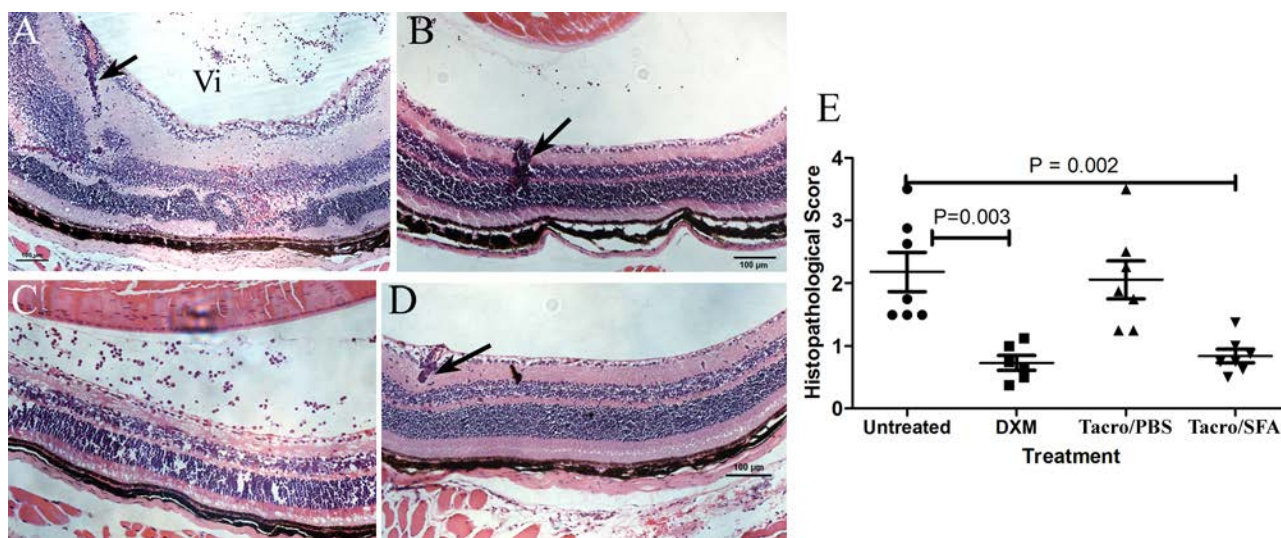
The levels of tacrolimus in the vitreous humour collected at 15 minutes to 2 h after Tacrolimus/SFA eyedrop treatment were between 2 ~ 6 ng/ml. By 4 h and 6 h, the level of tacrolimus was below detectable



**Fig. (2).** Histopathology of EIU in different groups of mice. EIU mice were treated with 0.1% dexamethasone (DXM), or 0.03% Tacrolimus/PBS, or 0.03% Tacrolimus/SFA eyedrops 3 times/day from day 0 to day 2. Eyes were collected on day 2 and processed for H-E staining. Light-microscopic images from (A) control untreated EIU mice, (B) Tacrolimus/PBS treated mice, (C) DXM treated mice, and (D) Tacrolimus/SFA treated mice. Arrows in (A) indicating retinal detachment; arrow in (B) indicating subretinal haemorrhage. (E) Histopathological score of retinal inflammation. One plot represents the score of one mouse (i.e., the average score of two eyes of a mouse). Mann-Whitney test. AC – anterior chamber; CB – ciliary body; Ir – iris; Vi – vitreous; Re – retina.



**Fig. (3).** The effects of Tacrolimus/SFA eyedrop on clinical presentation of EAU. EAU was induced in C57BL/6J mice using IRBP<sub>1-20</sub> peptide immunisation. On day 14, mice were treated with different eyedrops 3 times/day. Fundus images were taken on day 25 post-immunisation from a control untreated EAU mouse (A), 0.03% Tacrolimus/PBS treated (B), 0.1% DXM treated (C), and 0.03% Tacrolimus/SFA treated (D) mice. Arrows in (A) and (D) indicating vascular cuffing; arrowhead in (A) indicating linear lesion. (E) Changes in clinical score of EAU from day 14 p.i. to 25 p.i. in different groups. Wilcoxon matched pairs test. (F) Comparing of clinical score of EAU on day 25 p.i. in different groups. Mann-Whitney test.



**Fig. (4).** Histopathology of EAU in different groups of mice. EAU mice were treated with 0.1% dexamethasone (DXM), or 0.03% Tacrolimus/SFA eyedrops 3 times/day from day 14 to day 24. Eyes were collected on day 25 and processed for H-E staining. Light-microscopic images of (A) control untreated EAU mice, (B) DXM treated mice, (C) Tacrolimus/PBS treated mice, and (D) Tacrolimus/SFA treated mice. Arrows indicating granuloma lesions. (E) Histopathological score of retinal inflammation. One plot represents the score of one mouse (i.e., the average score of two eyes of a mouse). Mann-Whitney test.

level in most of the samples in Tacrolimus/SFA treated mice. In Tacrolimus/PBS treated mice the Tacrolimus level was below the detectable level in all samples apart from those from 1 h. The level of Tacrolimus in the vitreous from Tacrolimus/SFA group was significantly higher than those from Tacrolimus/PBS group at 1 h after administration (Fig. 5A).

In the choroid/sclera, high levels of tacrolimus were detected at 15 minutes to 1 h after Tacrolimus/SFA eyedrop administration (276 ng/g tissue ~ 337 ng/g tissue, Fig. 5B). The levels then reduced to 150 ng/g tissue at 2 h and 70 ng/g tissue at 6 h (Fig. 5B). In eyes treated with Tacrolimus/PBS, 23 ng/g and 34 ng/g tissue of tacrolimus were detected between 15 min and 1 h, and the levels reduced to 8 ng/g tissue by 6 h (Fig. 5B). The levels of tacrolimus in the choroid/sclera in the Tacrolimus/SFA group at all time points were significantly higher than those in Tacrolimus/PBS group (Fig. 5B).

The levels of tacrolimus in the retina in the Tacrolimus/SFA were 48 ng/g tissue at 15 min after eyedrop administration, and increased to 90 ng/g tissue by 1 h (Fig. 5C). The levels of tacrolimus decreased slightly after 2 h, but remained at 53 ng/g tissue at 6 h after eyedrop treatment (Fig. 5C). In eyes treated with Tacrolimus/PBS, the levels of tacrolimus were between 2-8 ng/g tissue at all time points and were significantly lower than those in eyes treated with Tacrolimus/SFA (Fig. 5C).

The level of Tacrolimus in the blood of normal mice treated with Tacrolimus/SFA increased from 35 ng/ml at 15 minutes to 118 ng/ml at 30 minutes and then reduced from 1 h but remained at 62 ng/ml at 2 h after treatment (Fig. 5D). Lower levels of tacrolimus (2-40 ng/ml) were detected in the blood in mice treated with

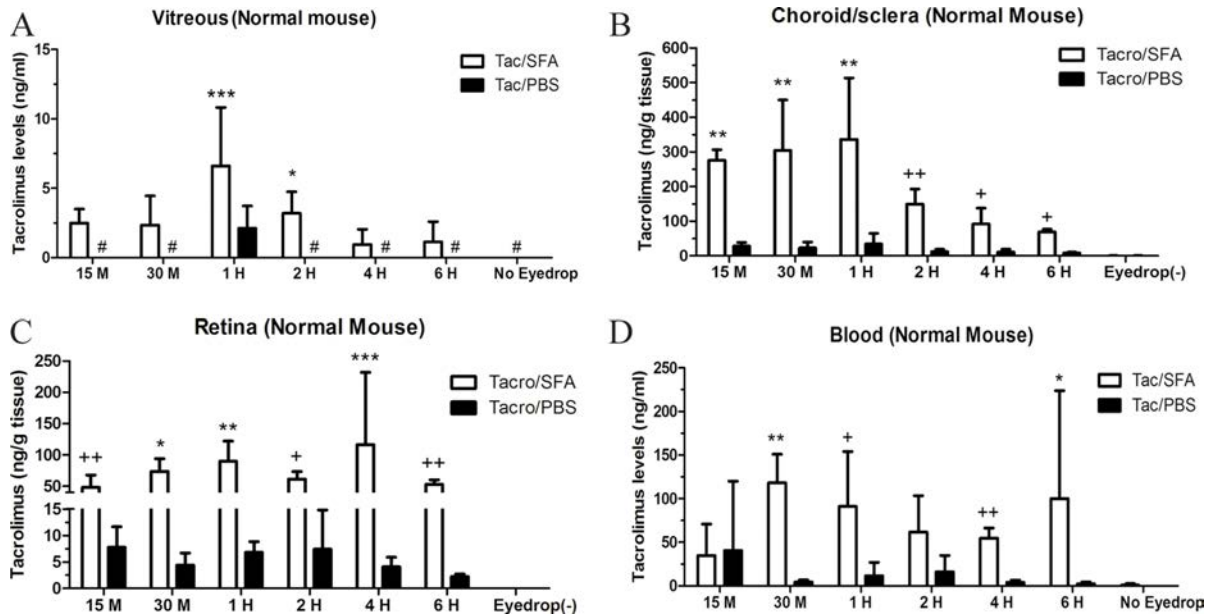
Tacrolimus/PBS eyedrop, although the levels were not statistically higher than those in untreated controls mice (Fig. 5D). The blood levels of tacrolimus in Tacrolimus/SFA group were significantly higher than those in Tacrolimus/PBS group at 30 min, 1 h, and 4 h time points (Fig. 5D).

Our results suggest that Tacrolimus/SFA has a greater permeability than Tacrolimus/PBS, and can rapidly penetrate ocular barriers in normal mouse eyes and distribute to all ocular tissues as well as the blood circulation rapidly (within 15 ~ 30 min) after eyedrop administration.

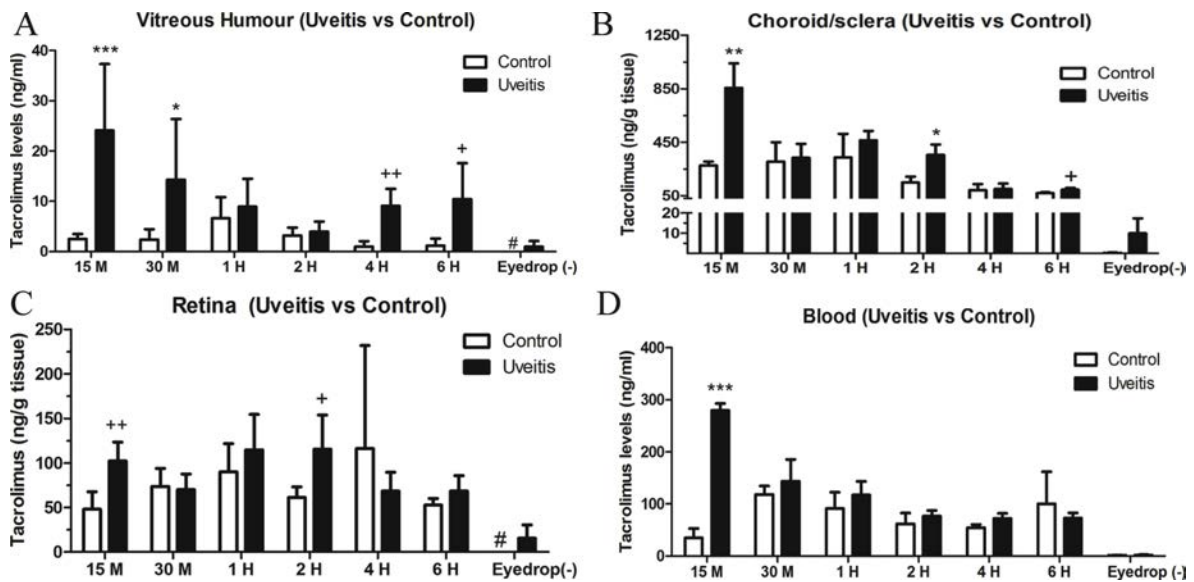
### 3.3.2. Pharmacokinetics and absorption of Tacrolimus eyedrop in uveitis mice:

Only Tacrolimus/SFA was tested in the uveitis eyes. Therefore, we compared the pharmacokinetics of Tacrolimus/SFA eyedrop between uveitis eyes and non-uveitis eyes. The levels of tacrolimus in the vitreous of uveitis mice were 24 ng/ml and 14 ng/ml at 15 min and 30 min respectively, significantly higher than those in non-uveitis mice (2.5 ng/ml and 2.3 ng/ml respectively). Six hours after eyedrop administration 10 ng/ml of Tacrolimus were detected in the vitreous of uveitis eyes compared to 1.1 ng/ml in non-uveitis eyes (Fig. 6A).

The level of Tacrolimus in the choroid/sclera was 855.5 ng/g tissue at 15 min after eyedrop administration in uveitis mice compared to 276 ng/g tissue in normal mice (Fig. 6B). The concentrations of Tacrolimus decreased at 30 min and 1 h in uveitis eyes to the levels that were comparable to non-uveitis eye. At 2 h and 6 h, uveitis mice had significantly higher levels of Tacrolimus compared to normal non-inflamed mice (Fig. 6B).



**Fig. (5).** Tacrolimus levels in the vitreous, choroid/sclera, retina and blood of normal mouse eyes. Mice were given Tacrolimus/SFA or Tacrolimus/PBS eyedrop 3 times/day for 3 days. At different times after the last eyedrop treatment samples were collected and processed for measurement of Tacrolimus using the liquid chromatography tandem mass spectrometry (LC-MS/MS) method. (A) Vitreous. (B) Choroid/sclera tissues. (C) Retinal tissues. The level of tacrolimus was normalized to tissue weight in retina and choroid/sclera. (D) Whole blood. Mean  $\pm$  SD. N = 4, \*P<0.05, \*\*P<0.01, \*\*\*P<0.001 compared to Tacrolimus/PBS treated eyes at the same time point, 2-way ANOVA. +P<0.05, ++P<0.01 compared to Tacrolimus/PBS treated eyes at the same time point, unpaired *t* test. #, values below detectable in assay.



**Fig. (6).** Tacrolimus levels in the vitreous of mouse eyes with and without uveitis. Control non-uveitis mice and uveitis mice were given Tacrolimus/SFA eyedrop 3 times/day for 3 days. At different times after the last eyedrop treatment samples were collected. (A) Vitreous. (B) Choroid/sclera tissues. (C) Retinal tissues. The level of tacrolimus was normalized to tissue weight in retina and choroid/sclera. (D) Whole blood. Mean  $\pm$  SD. N = 4, \*P<0.05, \*\*P<0.01, \*\*\*P<0.001 compared to control non-uveitis eyes at the same time point. 2-way ANOVA. +P<0.05, ++P<0.01 compared to non-uveitis eyes at the same time point, unpaired *t* test. #, below detectable value in assay.

Significantly higher levels of tacrolimus were detected in the retina of uveitis mice compared to that of non-uveitis mice after 15 min (102 vs. 48 ng/g tissue) and 2 h (115 ng/g vs. 61 ng/g tissue) (Fig. 6C) of administration. The level of retinal tacrolimus at 6 h

was approximately 67% of that in 15 min in uveitis eyes (Fig. 6C).

The blood level of Tacrolimus was to 280 ng/ml in uveitis mice 15 min after administration, significantly

higher than that in non-uveitis mice (35 ng/ml) (Fig. 6D). The levels then decreased in uveitis mice to 143 ng/ml at 30 min and to 73 ng/ml at 6 h after eyedrop treatment. In non-inflamed mice, the blood levels of Tacrolimus increased at 30 min to the 118 ng/ml, and remained at the levels comparable to uveitis mice at other time points (Fig. 6D).

#### 4. DISCUSSION

Oral administration of tacrolimus is effective in uveitis refractory to corticosteroids and cyclosporine [15-17, 28]. Recent studies in non-infectious posterior uveitis patients have shown that tacrolimus monotherapy is as effective as the tacrolimus plus prednisone dual therapy in maintaining disease remission [29]. However, long-term systemic administration can cause tacrolimus intolerance [18]; therefore, local administration of tacrolimus would be an ideal option. Previous studies have demonstrated that intravitreal injection of tacrolimus is effective in controlling inflammation in experimental models of uveitis [30-32]. In this study, we show that 0.03% Tacrolimus/SFA eyedrop suppressed intraocular inflammation in both EIU and EAU models. Importantly, we show that Tacrolimus/SFA can rapidly penetrate ocular barrier at high levels, particularly in EIU eyes. Tacrolimus/PBS did not show any suppressive effect in EIU and EAU models, and it was unable to penetrate ocular barriers. Our results suggest that 0.03% Tacrolimus/SFA may be a novel therapy for intraocular inflammation.

Tacrolimus has a poor ability to penetrate tissue barrier upon topical administration due to its physico-chemical properties [33]. Currently, a few tacrolimus formulations are being tested for ocular surface disorders such as allergic conjunctivitis [34-37], dry eye conditions [38], and high-risk corneal transplantation [39]. The formulas include 0.03% tacrolimus eye ointment (Protopic) and 0.03% tacrolimus eyedrop (Olive oil + 0.03% Tacrolimus, Ophthalmos Pharma, São Paulo, Brazil), 0.1% Tacrolimus ophthalmic suspension (Senju Pharmaceutical Co., Osaka, Japan), and 0.1% tacrolimus ophthalmic eye ointment (Tacimus-Ajanta Pharmaceuticals, India). The use of topical administration of tacrolimus to treat intraocular inflammation has not been reported, probably because none of the aforementioned products are capable of penetrating ocular barrier with therapeutic concentrations.

Recent studies have shown that semifluorinated alkanes act as an effective carrier for lipophilic drug cyclosporine for topical delivery [40]. In this study, we have used formulations of semifluorinated alkanes to dissolve tacrolimus. This formulation allows 0.03% tacrolimus to be dissolved completely to form a clear solution. The pharmacokinetic study suggests that Tacrolimus/SFA, but not Tacrolimus/PBS could rapidly (within 15 minutes) penetrate the tissue barriers (e.g., epithelial, membranes and endothelial barriers) after topical administration and reach choroid/sclera at significant levels in normal mouse. At the same time a

significant level of tacrolimus was observed in blood circulation. This is most likely due to direct absorption of tacrolimus from the ocular surface through the conjunctival vascular network. High blood levels of tacrolimus (along with local absorption) might contribute to high concentrations of tacrolimus in the choroid/sclera.

Absorption of tacrolimus is much increased when the eye is inflamed, and the levels of tacrolimus in the choroid/sclera and blood of uveitis mice were 3 and 8 times higher than those in non-uveitis mice 15 min after administration.

Tacrolimus/SFA can penetrate not only general tissue barrier, but also the ocular barrier. Significant amounts of tacrolimus were detected in the vitreous and retina 15 min after topical administration and the drug remained in the retina for at least 6 h in normal mouse eyes. Further analysis is necessary to identify the source of intraocular tacrolimus, i.e., from the ciliary body and choroid or systemic blood circulation (*via* the inner BRB).

The levels of tacrolimus in the vitreous and retina were 2 and 10 times higher in uveitis eye than those in non-uveitis eyes at 15 min after administration. The pharmacokinetic data may explain the therapeutic effect of 0.03% Tacrolimus/SFA in the EIU and EAU models observed in this study.

A previous study in rabbit eyes using the 0.05% Tacrolimus suspension eyedrop has shown that the maximum concentrations of tacrolimus in the aqueous humour after a single dose and multiple doses of topical administrations were 31.4 ng/ml and 37 ng/ml respectively [41]. Another study showed that 1 h after 1% Tacrolimus suspension eyedrop treatment, the drug concentrations in the conjunctiva, cornea, iris, and anterior sclera were 148, 900, 120, and 145 ng/g tissue, respectively, whereas the vitreous body concentration ( $C_{max}$ ) was only 1.4 ng/ml [42]. The present study in mice showed that 0.03% Tacrolimus eyedrop penetrates the ocular barrier (within 15 minutes) and reach to intraocular tissues at high levels (2-6 ng/ml in the vitreous body and 48-116 ng/g tissue in the retina of normal mouse eyes).

The blood concentration of tacrolimus detected in this study after eyedrop administration in mice (34 ~ 118 ng/ml in normal mice; 72 ~ 280 ng/ml in uveitis mice) was significantly higher than that reported in the rabbit study ( $C_{max}$  2.7 ng/ml, after topical administration of 1% Tacrolimus suspension) [42]. It was also higher than that in human solid organ transplantation after systemic administration (trough blood concentration: 5 ~ 20 ng/ml) [43]. The discrepancies between our study and others may be due to the volume of eyedrop (e.g., standard drop size was used and not adjusted to the animal eye size), but more likely due to the higher penetration and large absorption area resulting from improved spreading of the Tacrolimus/SFA compared to 1% Tacrolimus suspension used in previous studies [42]. In our eyedrop formulation, tacrolimus is dissolved in SFA and therefore is available for absorption,



whereas the undissolved tacrolimus particles in the 1% suspension might be removed from, instead of absorbed by, the eye. Furthermore, difference in body size and in physiology and anatomy of the eyes between mouse, rabbit and man has to be considered when translating the results to humans [44, 45]. Therefore, further pharmacokinetics study in the rabbit or human eyes may help determine the clinical applications of 0.03% Tacrolimus/SFA in inflammatory ocular conditions.

## CONCLUSION

In conclusion, the data suggest that Tacrolimus/SFA is able to penetrate ocular barriers in mice, reach intraocular tissue at therapeutic levels and suppress retinal inflammation. Topical application of Tacrolimus/SFA should have a potential in the management of inflammatory eye diseases such as uveitis although further studies are necessary to evaluate the long-term safety of this eyedrop and its therapeutic effects on recurrent or chronic uveitis.

## DISCLOSURES

This project is funded by Novaliq GmbH. MS, JK, AP and DS are employees of Novaliq GmbH. Novaliq has filed a patent application to European Union on Tacrolimus/SFA formulation.

## ETHICS APPROVAL AND CONSENT TO PARTICIPATE

Not applicable.

## HUMAN AND ANIMAL RIGHTS

No humans were used for studies that are base of this research.

## CONSENT FOR PUBLICATION

Not applicable.

## CONFLICT OF INTEREST

The authors declare no conflict of interest, financial or otherwise.

## ACKNOWLEDGEMENTS

The authors thank Dr. Jose R. Hombrebueno for technical assistance in mouse vitreous humour collection. Funding support is provided by Novaliq GmbH.

## REFERENCES

- Rosenbaum JT, Martin TM, Planck SR. Anterior uveitis: clinical and research perspectives. Springer Semin Immunopathol 1999; 21: 135-45.
- Hwang DK, Chou YJ, Pu CY, *et al.* Epidemiology of uveitis among the Chinese population in Taiwan: a population-based study. Ophthalmology 2012; 119: 2371-6.
- Nussenblatt RB. Immunoregulation of uveitis. Int Ophthalmol 1990; 14: 13-8.
- Thorne JE, Suhler E, Skup M, *et al.* Prevalence of Noninfectious Uveitis in the United States: A Claims-Based Analysis. JAMA Ophthalmol 2016; 134: 1237-45.
- Rathinam SR, Krishnadas R, Ramakrishnan R, *et al.* Population-based prevalence of uveitis in Southern India. Br J Ophthalmol 2011; 95: 463-7.
- Luger D, Silver PB, Tang J, *et al.* Either a Th17 or a Th1 effector response can drive autoimmunity: conditions of disease induction affect dominant effector category. J Exp Med 2008; 205: 799-810.
- Luger D, Caspi RR. New perspectives on effector mechanisms in uveitis. Semin Immunopathol 2008; 30: 135-43.
- Jaffe GJ, Martin D, Callanan D, *et al.* Fluocinolone acetonide implant (Retisert) for noninfectious posterior uveitis: thirty-four-week results of a multicenter randomized clinical study. Ophthalmology 2006; 113: 1020-7.
- Kok H, Lau C, Maycock N, *et al.* Outcome of intravitreal triamcinolone in uveitis. Ophthalmology 2005; 112: 1916.e1-7.
- Sallam A, Taylor SR, Habot-Wilner Z, *et al.* Repeat intravitreal triamcinolone acetonide injections in uveitic macular oedema. Acta Ophthalmol 2012; 90: e323-5.
- Kino T, Hatanaka H, Hashimoto M, *et al.* FK-506, a novel immunosuppressant isolated from a Streptomyces. I. Fermentation, isolation, and physico-chemical and biological characteristics. J Antibiot (Tokyo) 1987; 40: 1249-55.
- Sawada S, Suzuki G, Kawase Y, *et al.* Novel immunosuppressive agent, FK506. In vitro effects on the cloned T cell activation. J Immunol 1987; 139: 1797-803.
- Peters DH, Fitton A, Plosker GL, *et al.* Tacrolimus. A review of its pharmacology, and therapeutic potential in hepatic and renal transplantation. Drugs 1993; 46: 746-94.
- Kino T, Inamura N, Sakai F, *et al.* Effect of FK-506 on human mixed lymphocyte reaction in vitro. Transplant Proc 1987; 19: 36-9.
- Mochizuki M, Masuda K, Sakane T, *et al.* A multicenter clinical open trial of FK 506 in refractory uveitis, including Behcet's disease. Japanese FK 506 Study Group on Refractory Uveitis. Transplant Proc 1991; 23: 3343-6.
- Ishioaka M, Ohno S, Nakamura S, *et al.* FK506 treatment of noninfectious uveitis. Am J Ophthalmol 1994; 118: 723-9.
- Kilmartin DJ, Forrester JV, Dick AD. Tacrolimus (FK506) in failed cyclosporin A therapy in endogenous posterior uveitis. Ocul Immunol Inflamm 1998; 6: 101-9.
- Hogan AC, McAvoy CE, Dick AD, *et al.* Long-term efficacy and tolerance of tacrolimus for the treatment of uveitis. Ophthalmology 2007; 114: 1000-6.
- Meinert H, Roy T. Semifluorinated alkanes--a new class of compounds with outstanding properties for use in ophthalmology. Eur J Ophthalmol 2000; 10: 189-97.
- Broniatowski M, Dynarowicz-Latka P. Semifluorinated alkanes--primitive surfactants of fascinating properties. Adv Colloid Interface Sci 2008; 138: 63-83.
- Chen M, Muckersie E, Luo C, *et al.* Inhibition of the alternative pathway of complement activation reduces inflammation in experimental autoimmune uveoretinitis. Eur J Immunol 2010; 40: 2870-81.
- Chen M, Copland DA, Zhao J, *et al.* Persistent inflammation subverts thrombospondin-1-induced regulation of retinal angiogenesis and is driven by CCR2 ligation. Am J Pathol 2012; 180: 235-45.
- Xu H, Manivannan A, Dawson R, *et al.* Differentiation to the CCR2+ Inflammatory Phenotype In Vivo Is a Constitutive, Time-Limited Property of Blood Monocytes and Is Independent of Local Inflammatory Mediators. J Immunol 2005; 175: 6915-23.
- Becker MD, Garman K, Whitcup SM, *et al.* Inhibition of leukocyte sticking and infiltration, but not rolling, by antibodies to ICAM-1 and LFA-1 in murine endotoxin-induced uveitis. Invest Ophthalmol Vis Sci 2001; 42: 2563-6.
- Rosenbaum JT, Woods A, Kezic J, *et al.* Contrasting ocular effects of local versus systemic endotoxin. Invest Ophthalmol Vis Sci 2011; 52: 6472-7.

- [26] Xu H, Koch P, Chen M, *et al.* A clinical grading system for retinal inflammation in the chronic model of experimental autoimmune uveoretinitis using digital fundus images. *Exp Eye Res* 2008; 87: 319-26.
- [27] Agarwal RK, Silver PB, Caspi RR. Rodent models of experimental autoimmune uveitis. *Methods Mol Biol* 2012; 900: 443-69.
- [28] Sloper CM, Powell RJ, Dua HS. Tacrolimus (FK506) in the treatment of posterior uveitis refractory to cyclosporine. *Ophthalmology* 1999; 106: 723-8.
- [29] Lee RW, Greenwood R, Taylor H, *et al.* A randomized trial of tacrolimus versus tacrolimus and prednisone for the maintenance of disease remission in noninfectious uveitis. *Ophthalmology* 2012; 119: 1223-30.
- [30] Zhang R, He R, Qian J, *et al.* Treatment of experimental autoimmune uveoretinitis with intravitreal injection of tacrolimus (FK506) encapsulated in liposomes. *Invest Ophthalmol Vis Sci* 2010; 51: 3575-82.
- [31] Souza MC, Fialho SL, Souza PA, *et al.* Tacrolimus-loaded PLGA implants: in vivo release and ocular toxicity. *Curr Eye Res* 2014; 39: 99-102.
- [32] Ishikawa T, Hokama H, Katagiri Y, *et al.* Effects of intravitreal injection of tacrolimus (FK506) in experimental uveitis. *Curr Eye Res* 2005; 30: 93-101.
- [33] Tamura S, Ohike A, Ibuki R, *et al.* Tacrolimus is a class II low-solubility high-permeability drug: the effect of P-glycoprotein efflux on regional permeability of tacrolimus in rats. *J Pharm Sci* 2002; 91: 719-29.
- [34] Attas-Fox L, Barkana Y, Iskhakov V, *et al.* Topical tacrolimus 0.03% ointment for intractable allergic conjunctivitis: an open-label pilot study. *Curr Eye Res* 2008; 33: 545-9.
- [35] Fukushima A, Ohashi Y, Ebihara N, *et al.* Therapeutic effects of 0.1% tacrolimus eye drops for refractory allergic ocular diseases with proliferative lesion or corneal involvement. *Br J Ophthalmol* 2014; 98: 1023-7.
- [36] Ghanem RC, Vargas JF, Ghanem VC. Tacrolimus for the treatment of subepithelial infiltrates resistant to topical steroids after adenoviral keratoconjunctivitis. *Cornea* 2014; 33: 1210-3.
- [37] Barot RK, Shitole SC, Bhagat N, *et al.* Therapeutic effect of 0.1% Tacrolimus Eye Ointment in Allergic Ocular Diseases. *J Clin Diagn Res* 2016; 10: NC05-9.
- [38] Moscovici BK, Holzchuh R, Chiacchio BB, *et al.* Clinical treatment of dry eye using 0.03% tacrolimus eye drops. *Cornea* 2012; 31: 945-9.
- [39] Magalhaes OA, Marinho DR, Kwitko S. Topical 0.03% tacrolimus preventing rejection in high-risk corneal transplantation: a cohort study. *Br J Ophthalmol* 2013; 97: 1395-8.
- [40] Dutescu RM, Panfil C, Merkel OM, *et al.* Semifluorinated alkanes as a liquid drug carrier system for topical ocular drug delivery. *Eur J Pharm Biopharm* 2014; 88: 123-8.
- [41] Yuan J, Zhai JJ, Chen JQ, *et al.* Preparation of 0.05% FK506 suspension eyedrops and its pharmacokinetics after topical ocular administration. *J Ocul Pharmacol Ther* 2009; 25: 345-50.
- [42] Fujita E, Teramura Y, Shiraga T, *et al.* Pharmacokinetics and tissue distribution of tacrolimus (FK506) after a single or repeated ocular instillation in rabbits. *J Ocul Pharmacol Ther* 2008; 24: 309-19.
- [43] Wallemacq P, Armstrong VW, Brunet M, *et al.* Opportunities to optimize tacrolimus therapy in solid organ transplantation: report of the European consensus conference. *Ther Drug Monit* 2009; 31: 139-52.
- [44] Treuting PM, Dintzis SM. *Comparative Anatomy and Histology: A Mouse and Human Atlas (Expert Consult)*. Academic Press, 2011; 474.
- [45] Gilger BC. *Ocular Pharmacology and Toxicology*. Springer Science+Business Media: New York, 2014; 89.